

# SPONTANI RETROPERITONEALNI HEMATOM KOD PACIJENTA OBOLELOG OD KOVID-19 INFEKCIJE

PRIKAZ SLUČAJA

CASE REPORT

## SPONTANEOUS RETROPERITONEAL HEMATOMA IN A COVID-19 PATIENT

Ana Sekulić<sup>1,2</sup>, Olivera Marinković<sup>1</sup>, Davor Mrda<sup>1</sup>, Borislav Tošković<sup>1,2</sup>, Marija Zdravković<sup>1,2</sup>, Predrag Đuran<sup>1</sup>

<sup>1</sup> Kliničko-bolnički centar „Bežanijska kosa“, Beograd, Srbija

<sup>2</sup> Medicinski fakultet, Univerzitet u Beogradu, Beograd, Srbija

<sup>1</sup> University Hospital Medical Center Bežanijska kosa, Belgrade, Serbia

<sup>2</sup> Faculty of Medicine, University of Belgrade, Belgrade, Serbia

### SAŽETAK

**Uvod:** Poznato je da infekcija SARS-CoV-2 virusom izaziva hiperkoagulabilno stanje koje rezultira akutnim trombotičnim događajima. Tromboembolijski događaji javljaju se u čak 21,0% slučajeva sa stopom mortaliteta od oko 74,0%, kod osoba zaraženih ovim virusom. Antikoagulansi se koriste u teškim KOVID-19 infekcijama, za sprečavanje tromboze, i pokazalo se da smanjuju smrtnost. Upotreba antikoagulanasa nije bez rizika. Komplikacije krvarenja mogu da variraju od lakših do teških ili čak opasnih po život, kao što je retroperitonealno krvarenje u mišić psosas.

**Prikaz bolesnika:** Ovde predstavljamo slučaj bolesnika koji je tokom lečenja obostrane bronhopneumonije izazvane SARS-CoV-2 virusom razvio komplikaciju krvarenja u retroperitonealni prostor. Nakon uspostavljene dijagnoze, na osnovu kliničkog pregleda, laboratorijskih i radioloških pretraga i inicijalnog konzervativnog lečenja u KBC „Bežanijska kosa“, bolesniku je u proceduralnoj analgosedaciji urađena embolizacija lumbalnih arterija levo, iz desne preponske jame. Nakon urađene interventne radiološke procedure, oporavak je bio zadovoljavajući, ali je, zbog nemogućnosti resorpcije inkapsuliranog hematoma sa zonom centralne nekroze, urađena mini leva lumbotomija i evakuacija istog. Bolesnik je otpušten na kućno lečenje dvadeset trećeg dana od prijema, u stabilnom opštem stanju.

**Zaključak:** Praćenje dejstva antikoagulantne terapije, naročito kod pacijenata sa prisutnim faktorima rizika, rana dijagnostika i blagovremena terapija spontanih retroperitonealnih hematoma je imperativ za smanjenje mortaliteta od ove teške komplikacije kod pacijenata sa KOVID-19 infekcijom.

**Cljučne reči:** retroperitonealni hematom, KOVID-19, arterijska embolizacija

### ABSTRACT

**Introduction:** The infection caused by the SARS-CoV-2 virus is known to cause a hypercoagulable condition resulting in acute thrombotic events. Thromboembolic events occur in as many as 21.0% of cases with a mortality rate of about 74.0% in persons infected with COVID-19. Anticoagulant therapy is used in severe COVID-19 infections in order to prevent thrombosis and has been shown to reduce mortality. The use of anticoagulants is not without risks. Bleeding complications can range from mild to severe or even life-threatening, such as retroperitoneal bleeding into the psoas muscle.

**Case report:** We present a case of a patient who developed a complication of bleeding into the retroperitoneal space during the treatment of bilateral bronchopneumonia caused by the SARS-CoV-2 virus. After the diagnosis was established, on the basis of a clinical examination, laboratory and radiological examinations, and after initial conservative treatment at the UHMC *Bežanijska kosa*, the patient underwent embolization of the left lumbar arteries from the right inguinal fossa, during procedural analgosedation. After the radiological procedure, the recovery was satisfactory, but due to the impossibility of resorption of an encapsulated hematoma with a zone of central necrosis, a mini left lumbotomy and evacuation of the hematoma were performed. The patient was discharged from the hospital on the 23<sup>rd</sup> day of admission in stable general condition.

**Conclusion:** The effect of anticoagulant therapy, especially in patients with existing risk factors, early diagnosis, and prompt therapy of spontaneous retroperitoneal hematomas is imperative to reduce mortality from this severe complication, in patients with the COVID-19 infection.

**Key words:** retroperitoneal hematoma, COVID-19, arterial embolization

Autor za korespondenciju:

Ana Sekulić

Kliničko-bolnički centar „Bežanijska kosa“

Dr Žorža Matea bb, 11000 Beograd, Srbija

Elektronska adresa: annadjov@gmail.com

Corresponding author:

Ana Sekulić

University Hospital Medical Center "Bežanijska kosa"

Dr Žorža Matea Street, 11000 Belgrade, Serbia

E-mail: annadjov@gmail.com

**Primljeno • Received:** November 16, 2021; **Revidirano • Revised:** November 26, 2021; **Prihvaćeno • Accepted:** November 28, 2021; **Online first:** December 13, 2021.

DOI: 10.5937/smcl2-34956

## UVOD

Od početka pandemije SARS-KoV-2 virusa, 12. decembra 2019. godine, do današnjeg dana, bolest KOVID-19 je pokazala mnogo različitih kliničkih manifestacija. Respiratorni simptomi i groznica su česti kod većine pacijenata sa virusom SARS-KoV-2. Međutim, mogu biti uključeni i drugi sistemi [1]. Poznato je da KOVID-19 infekcija izaziva hiperkoagulabilno stanje, koje rezultira akutnim trombotičnim događajima, uključujući i vensku tromboemboliju, akutni infarkt miokarda, akutni moždani udar, akutnu ishemiju ekstremiteta. Tromboembolijski događaji javljaju se u čak 21,0% pacijenata, sa stopom mortaliteta od oko 74,0% kod osoba obolelih od KOVID-19 oboljenja [2].

Antikoagulansi se koriste u teškim oblicima KOVID-19 infekcije za sprečavanje tromboze i pokazalo se da smanjuju smrtnost. U Srbiji je trenutno u primeni dvanaesta verzija Protokola za lečenje pacijenata sa KOVID-19 infekcijom, sa jasno postavljenim indikacijama za primenu antikoagulantne terapije u profilaktičkim i terapijskim dozama (Tabela 1).

Upotreba antikoagulanasa nije bez rizika. Komplikacije krvarenja mogu da variraju od lakših do teških ili čak opasnih po život. Retroperitonealno krvarenje u mišić psoas može biti smrtonosno, zbog obilnog krvarenja pre nego što se pojave simptomi. Veoma je važno biti oprezan u dijagnostici i terapiji ove komplikacije. Klinički se retroperitonealno krvarenje može manifestovati hipotenzijom, bolom u stomaku ili padom hemoglobina. Praćenje dejstva antikoagulanasa je imperativ za smanjenje rizika od hemoragičnih događaja. Hemodinamski nestabilni pacijenti na antikoagulantnoj terapiji sa nepredvidivim velikim hematomima mekih tkiva mogu se lečiti arterijskom embolizacijom, jer je to minimalno invazivna procedura sa brzim terapijskim efektom, u poređenju sa hirurškim lečenjem.

Od početka pandemije KOVID-19 oboljenja do sada, u Kliničko-bolničkom centru „Bežanijska kosa“, učinjeno je oko 20 arterijskih embolizacija, kod pacijenata sa dijagnostikovanim retroperitonealnim hematomom, kao posledicom KOVID-19 infekcije. Ovde predstavljamo slučaj bolesnika koji je, tokom lečenja obostrane bronhopneumonije izazvane SARS-KoV-2 virusom, razvio komplikaciju krvarenja u retroperitonealni prostor.

## PRIKAZ SLUČAJA

Zbog velikog retroperitonealnog hematoma levo, muškarac starosti 65 godina primljen je u našu ustanovu, KBC „Bežanijska kosa“ iz privremene kovid bolnice na Beogradskom sajmu, gde je 21 dan lečen od bilateralne pneumonije izazvane SARS-KoV-2 virusom. Bolesnik je od ranije bio na antihipertenzivnoj i oralnoj antikoagulantnoj terapiji, zbog trostrukog bajpasa i zamenjene

## INTRODUCTION

Since the beginning of the pandemic of the SARS-CoV-2 virus, on December 12, 2019, until now, the COVID-19 disease has shown many different clinical manifestations. Respiratory symptoms and fever are common in most patients infected with SARS-CoV-2. However, other systems may be involved as well [1]. It is known that COVID-19 causes the hypercoagulable state, resulting in acute thrombotic events, including venous thromboembolism, acute myocardial infarction, acute stroke, and acute ischemia of the extremities. Thromboembolic events occur in as many as 21.0% of patients, with a mortality rate of around 74.0% in COVID-19 patients [2].

Anticoagulants are used in severe forms of the COVID-19 infection for preventing thrombosis and they have proven to reduce mortality. At the moment, in Serbia, the 12<sup>th</sup> version of the Protocol for Treating Patients with the COVID-19 Infection is in use and it clearly defines indications for the application of anticoagulant therapy in prophylactic and therapeutic doses (Table 1).

The application of anticoagulants is not without risk. Complications of bleeding may vary from mild to severe or even life-threatening. Retroperitoneal bleeding into the psoas muscle may be lethal, due to profuse bleeding that occurs before symptoms appear. It is very important to be cautious in the diagnosis and treatment of this complication. Clinically, retroperitoneal bleeding can manifest in the form of hypotension, abdominal pain or a drop in hemoglobin. Monitoring the effect of anticoagulants is an imperative for decreasing the risk of hemorrhagic events. Hemodynamically unstable patients on anticoagulant therapy with unpredictable large hematoma of the soft tissues may be treated with arterial embolization, as it is a minimally invasive procedure with a rapid therapeutic effect, as compared to surgical treatment.

Since the beginning of the COVID-19 pandemic until now, at the University Hospital Medical Center *Bežanijska kosa*, a total of approximately 20 arterial embolization procedures was performed, in patients with diagnosed retroperitoneal hematoma resulting from the COVID-19 infection. In this case report, we present the case of a patient who, during treatment of bilateral pneumonia caused by SARS-CoV-2, developed the complication of bleeding into the retroperitoneal space.

## CASE REPORT

Due to a large retroperitoneal hematoma on the left side, a 65-year-old male patient was admitted to our hospital, UHMC *Bežanijska kosa*, from the temporary COVID-19 hospital at the Belgrade Fair, where he had been treated for 21 days for bilateral pneumonia caused by SARS-CoV-2. The patient had previously been on antihypertensive and oral anticoagulant therapy, due to a

**Tabela 1.** Protokol za lečenje pacijenata sa KOVID-19 infekcijom – Verzija 12

**Table 1.** Protocol for Treating Patients with COVID-19, Version 12

<b>Hospitalizovani pacijenti / Hospitalized patients</b>	
Jedinice intenzivne nege, odnosno pacijenti na HF-u, CPAP-u, NIV-u, mehaničkoj ventilaciji, vazopresorima, inotropima / <i>Intensive care units, i.e., patients on HF, CPAP, NIV, mechanical ventilation, vasopressors, inotropes</i>	Standardne profilaktičke doze LMWH-a / <i>Standard prophylactic doses of LMWH</i>
Odeljenje, odnosno pacijenti koji NE zahtevaju HF, CPAP, NIV, mehaničku ventilaciju, vazopresore, inotropne / <i>Patients on wards, i.e., patients who do NOT require HF, CPAP, NIV, mechanical ventilation, vasopressors, inotropes</i>	Terapijske doze LMWH <sup>8</sup> / <i>Therapeutic doses of LMWH<sup>8</sup></i>
Sumnja na razvoj ili potvrđena venska tromboza / <i>Suspected development of venous thrombosis or confirmed venous thrombosis</i>	Terapijske doze LMWH-a ili DOAK-a <sup>2</sup> / <i>Therapeutic doses of LMWH or DOAC<sup>2</sup></i>
Pacijenti na dugotrajnoj antikoagulantnoj terapiji / <i>Patients on long-term anticoagulant therapy</i>	Terapijske doze LMWH-a ili DOAK-a <sup>2</sup> / <i>Therapeutic doses of LMWH or DOAC<sup>2</sup></i>
Nakon otpusta / <i>Patients after discharge from hospital</i>	Tromboprofilaksa nakon otpusta se <b>NE</b> preporučuje. Kod pacijenata koji imaju anamnestički podatak o tromboznom događaju u anamnezi, podatak o nedavno sprovedenoj hirurškoj intervenciji, značajno redukovanoj pokretljivosti, aktivnom malignitetu, kao i drugim značajnim protrombogenim stanjima, može se razmotriti tromboprofilaksa nakon otpusta / <i>Thromboprophylaxis after discharge is NOT recommended.</i> <i>In patients who, in their anamnesis, have a record of a thrombotic event, or of a recent surgical procedure, a record of significantly reduced mobility, or of an active malignancy, as well as a record of any other significant prothrombogenic state, thromboprophylaxis upon discharge may be considered</i>

<sup>8</sup> Na osnovu rezultata RCT publikovanog u *NEJM*-u, avgusta 2021. godine (ATTACC Investigators et al. Anticoagulation with Heparin in Noncritically Ill Patients with Covid-19. *N Engl J Med.* 2021 Aug 26;385(9):790-802. doi: 10.1056/NEJMoa2105911.)

<sup>1</sup> Sumnja na razvoj venske tromboze: unilateralan otok ekstremiteta; razvoj površinskog tromboflebitisa; razvoj disipnoičnih tegoba i/ili pogoršanje hipoksemije uprkos radiografskom/MSCT poboljšanju nalaza na plućima; porast SPDK-a; trend porasta D-dimera (vrednosti iznad 5, udvostručavanje vrednosti tokom 24 h).

U slučaju sumnje na razvoj arterijske tromboze preporučuje se konsultacija odgovarajućeg specijaliste: neurolog, kardiolog, vaskularni hirur.

<sup>2</sup> Za svaki lek iz grupe DOAK: proveriti doziranje; proveriti da li je potrebna prethodna parenteralna antikoagulantna terapija; proveriti interakcije sa ostalim lekovima koje pacijent koristi.

**NAPOMENA - Korekcije doze LMWH-a**

- Ako je broj trombocita ispod 25 - 50: redukcija doze LMWH-a za 50%.
- Ako je broj trombocita ispod 25: razmotriti ukidanje LMWH-a, uz procenu odnosa rizika - krvarenje/tromboza.
- Ako je ClCr ispod 30 ml/min: redukcija doze LMWH-a za 50% i dalje doziranje u skladu sa nalazom anti Xa. Standardno određivanje anti Xa se ne preporučuje.

**Legenda:** HF – engl. high-flow oxygen; CPAP – engl. continuous positive airway pressure therapy; NIV – neinvazivna ventilacija; LMWH – engl. low-molecular-weight heparin; DOAK – direktni orlni antikoagulantni lekovi; SPDK – sistolni pritisak desne komore; ClCr – engl. creatinine clearance; anti Xa – engl. anti-factor Xa assay

aortne valvule. Tokom lečenja KOVID-19 pneumonije bio je na terapiji niskomolekularnim heparinom u terapijskoj dozi. Pacijent je od ranije bio alergičan na penicilin.

Bolesnik je na prijemu bio svestan, komunikativan, orijentisan, afebrilan, blede prebojene kože i sluznice. Disao je sam i uz pomoć kiseonične maske je sa protokom od 10 L/min ostvarivao zadovoljavajući parcijalni pritisak kiseonika. Praćenjem hemodinamskih parametara uočena je hipotenzija sa sinusnom tahikardijom, a pacijent je imao očuvanu spontanu zadovoljavajuću diurezu. Fizikalnim pregledom su uočeni veliki podlivi u slabinskoj regiji i veliki otoci donjih ekstremiteta. Bili su prisutni i jaki bolovi u boku, hipovolemija i opipljiva masa u trbuhu. Od antibiotika, nastavljena je terapija

<sup>8</sup> Based on RCT result published in *NEJM*, August 2021 (ATTACC Investigators et al. Anticoagulation with Heparin in Noncritically Ill Patients with Covid-19. *N Engl J Med.* 2021 Aug 26;385(9):790-802. doi: 10.1056/NEJMoa2105911.)

<sup>1</sup> *S* Suspected development of venous thrombosis: unilateral swelling of one extremity; development of superficial thrombophlebitis; development of complaints of dyspnea and/or exacerbation of hypoxemia despite radiographic/MSCT improvement of pulmonary findings; elevation of RVSP; trend of D-dimer elevation (levels above 5, doubling of the level within 24 hours).

In case of suspicion of the development of arterial thrombosis it is recommended that the appropriate specialist should be consulted: neurologist, cardiologist, vascular surgeon

<sup>2</sup> For each drug from the DOAC group: check the dose; check whether previous parenteral anticoagulant therapy is necessary; check interactions with other drugs that the patient is taking

**NOTE – Corrections of LMWH doses**

- If the thrombocyte count is below 25 - 50: reduction of the LMWH dose by 50%.
- If the thrombocyte count is below 25: consider discontinuing LMWH, with the assessment of the risk ratio - bleeding/thrombosis.
- If ClCr is below 30 ml/min: reduction of the LMWH dose by 50% and further dosing in accordance with the findings of anti-Xa. Standard anti-Xa testing is not recommended.

**Legend:** HF – high-flow oxygen; CPAP – continuous positive airway pressure therapy; NIV – noninvasive ventilation; LMWH – low-molecular-weight heparin; DOAC – direct oral anticoagulants; RVSP – right ventricular systolic pressure; ClCr – creatinine clearance; anti Xa – anti-factor Xa assay

triple bypass and an aortic valve replacement. During the treatment of COVID-19 pneumonia, he was on low molecular weight heparin treatment, in therapeutic doses. The patient had previously displayed an allergy to penicillin.

At admission, the patient was conscious, communicative, oriented, afebrile, and his skin and mucosa were pale. He was breathing on his own, and with the help of an oxygen mask with a 10 L/min flow, he was achieving a satisfactory partial pressure of oxygen. The monitoring of hemodynamic parameters revealed hypotension with sinus tachycardia. The patient had a preserved satisfactory spontaneous 24-hour urine output. Physical examination revealed large hematomas in the lumbar region

meropenemom, vankomicinom i metronidazolom, uz redovnu kardiološku terapiju. Učinjen je snimak u ležećem stavu, u AP položaju.

Rentgenski snimak pluća i srca pokazao je stanje nakon medijalne sternotomije, vidljivu senku veštačke valvule, te centralni venski kateter (CVK) plasiran u desnu unutrašnju vratnu venu (*vena jugularis interna dextra*). U manjem delu plućnog parenhima uočene su fibrozne promene, kao i obostrani pleuralni izlivi, veći levo (Slika 1).

Nalaz CT aortografije: perihepatično, subhepatično, perisplenično, subsplenično, obostrano perikolično interintestinalno, u rektovezikalnom prostoru - veća količina slobodne tečnosti denziteta do 20 H; u levom hemiabdmenu, perikolično prisutna heterodenzna dominantno hipodenzna tumorska masa sa centralnim znacima nekroze, jasno ograničena, aproksimativnog dijametra 143x164x243mm, denziteta do 40 (Slika 2).

U krvnoj slici bila je izražena anemija, trombocitopenija, leukocitoza sa neutrofilijom i limfopenijom. Vrednost CRP-a bila je 38,4 mg/L. U biohemijskim analizama uočene su: hipoproteinemija, povišene vrednosti azotnih materija i transaminaza, uredni elektrolitni status. D-dimer je bio povišen i iznosio je 1.324 ng/mL.

Nakon kratkotrajne adekvatne pripreme, u proceduralnoj analgozsedaciji je urađena interventna terapijska procedura - embolizacija lumbalnih arterija levo, iz desne preponske jame, punkcijom desne zajedničke femoralne arterije (*arteria femoralis communis - AFC*), Seldingerovom metodom. Nakon što je učinjena kateterizacija

and significant swelling of the lower extremities. The following signs and symptoms were also present: severe pain in the side, hypovolemia, and a palpable mass in the abdomen. In terms of antibiotic therapy, treatment with meropenem, vancomycin, and metronidazole was continued, together with standard cardiological therapy. The patient was X-rayed while lying down in the AP position.

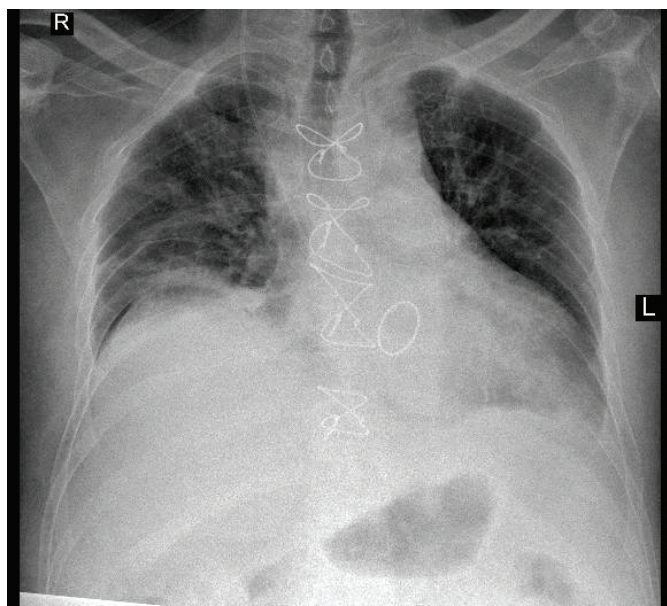
The chest X-ray showed evidence of previous median sternotomy, a visible shadow of the artificial valve, and a central venous catheter (CVC) placed in the right internal jugular vein (*vena jugularis interna dextra*). In a smaller portion of the pulmonary parenchyma, fibrous lesions were registered, as well as bilateral pleural effusions, the larger one positioned on the left side (Figure 1).

CT finding: perihepatically, subhepatically, perisplenically, subsplenically, bilaterally pericolicly interstitially, in the rectovesical space – a large quantity of free fluid with a density of 20 H; in the left hemi-abdomen, pericolicly – a heterodense, predominantly hypodense tumor mass with central signs of necrosis, clear margins, an approximate diameter of 143x164x243 mm, and a density of 40 H (Figure 2).

Blood work revealed marked anemia, thrombocytopenia, leukocytosis with neutrophilia and lymphopenia. The CRP level was 38.4 mg/L. Biochemical analyses showed the following: hypoproteinemia, increased levels of nitrogen compounds and transaminases, normal electrolyte status. The D-dimer was elevated and amounted to 1,324 ng/mL.

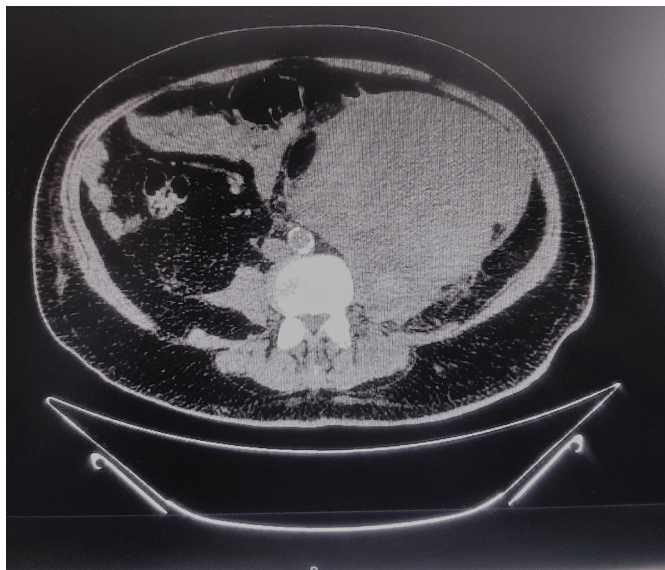
After brief and appropriate preparation, with the patient under procedural analgozsedation, an interventional therapeutic procedure was performed – embolization of the lumbar arteries on the left, approached from the right inguinal fossa, by puncturing the right femoral artery (*arteria femoralis communis - AFC*), applying the Seldinger technique. After the abdominal aorta was catheterized, only two lumbar arteries were angiographically detected on the left side. The first infrarenal lumbar artery was entered via catheter. Upon angiography, several smaller “blush” phenomena were detected. The artery was closed with one package of 600 µm *HydroPearl* embolization particles and one package of 400 µm *HydroPearl* embolization particles. Then, selective embolization of the distal lumbar artery was performed, and, after the appropriate positioning of the catheter, this artery was closed with four packages of 600 µm *HydroPearl* embolization particles. Both arteries were closed until complete stasis of the contrast medium was achieved. The immediate effects of the embolization were satisfactory.

The procedure was completed without complications. During the procedure, the patient was under analgozsedation, he was hemodynamically stable, tachycardic; he was receiving intravenous supplementation



**Slika 1.** Rentgenski snimak pluća i srca na prijemu u bolnicu  
U manjem delu plućnog parenhima vidljive su fibrozne promene. Obostrano se vide pleuralni izlivi, veći levo

**Figure 1.** Chest X-ray on admission to hospital  
In a smaller part of the pleural parenchyma fibrous changes are visible. Bilateral pleural effusions are present, the larger one can be seen on the left



**Slika 2.** CT snimak abdomena sa velikim retroperitonealnim hematomom, levo U levom hemiabdomenu, perikolično, prisutna je heterodenzna, dominantno hipodenzna, tumorska masa sa centralnim znacima nekroze, jasno ograničena, aproksimativnog dijametra 143x164x243 mm denziteta do 40 HU

**Figure 2.** CT scan of the abdomen with a large retroperitoneal hematoma on the left In the left hemiabdomen, a heterodense, predominantly hypodense tumor mass with central signs of necrosis is present, clearly limited to an approximate diameter of 143x164x243 mm, and with a density of up to 40 HU

abdominalne aorte, angiografski su detektovane samo dve lumbalne arterije na levoj strani. Kateterom se ušlo u prvu infrarenalnu lumbalnu arteriju. Nakon angiografije uočeno je postojanje nekoliko manjih „blush“ fenomena. Arterija je zatvorena jednim pakovanjem embolizacionih partikula *HydroPearl* od 600 mikrona i jednim pakovanjem embolizacionih partikula *HydroPearl* od 400 mikrona. Zatim je učinjena selektivna embolizacija distalne lumbalne arterije, koja je nakon adekvatnog pozicioniranja katetera zatvorena sa četiri pakovanja embolizacionih partikula *HydroPearl* od 600 mikrona. Obe arterije su zatvarane do potpune staze kontrastnog medijuma, Neposredni efekti embolizacije su bili zadovoljavajući.

Procedura je protekla bez komplikacija. Tokom intervencije, bolesnik je bio u analgosedaciji, hemodinamski stabilan, tahikardičan, uz intravensku nadoknadu cirkulišućeg volumena kristaloidnim rastvorima i transfuzijom koncentrovanih eritrocita. Nakon završetka intervencije, vraćen je u jedinicu intenzivnog lečenja gde je lečenje nastavljeno. U daljem toku, pacijent je bio hemodinamski stabilan i respiratorno svestan. U krvnoj slici se i dalje održavala anemija, koja se korigovala transfuzijom koncentrovanih eritrocita, i trombocitopenija. ROTEM test je pokazao nedovoljnu funkciju trombocita; bila je prisutna blaga do srednja hiperfibrinoliza; fibrinogenska aktivnost je bila funkcionalna, kao i aktivnost plazmatskih faktora. D-dimer je bio u porastu, a AT III normalnih vrednosti. Nastavljena

of the circulating volume through crystalloid solutions and transfusion of concentrated erythrocytes. After the procedure, the patient was returned to the intensive care unit, where treatment was continued. In the further course of recovery, the patient was hemodynamically stable, and breathing consciously. Blood work continued to show anemia, which was treated with transfusion of concentrated erythrocytes, and thrombocytopenia. The ROTEM test showed an insufficient platelet function; mild to medium hyperfibrinolysis was present; fibrinogenic activity was functional, as was the activity of plasma factors; D-dimer was rising, while AT III had normal values. Antibiotic treatment, according to the antibiogram, was continued. However, on the third day of treatment in our hospital, the patient developed diarrhea and *Clostridium difficile* was isolated. The antibiotic treatment was adjusted. Targeted peroral therapy with vancomycin and metronidazole was applied, in keeping with the national guidelines for treating the bacterium *Clostridium difficile*.

Laboratory analyses for this patient gradually improved, and, after the transfusion of blood and blood derivatives, the blood count was normalized; the platelet count rose; the D-dimer level decreased, which is why, on the sixth day after the procedure, a therapeutic dose of low molecular weight heparin (LMWH) was introduced. The patient was on combined enteral hyperproteic and parenteral nutrition. He was stabilized in terms of electrolytes and the metabolism and had satisfactory glucoregulation. Early rehabilitation treatment was carried out with the patient, and K-tape was used for large hematomas on the abdomen and legs, after retroperitoneal hematoma. In this phase, the patient regained flexion and extension of the hips and knees, which he did not have previously, due to excessive swelling of the extremities. Exercises in bed were continued as well as exercises of verticalization. In stable general condition, the patient was transferred to a surgical ward for further treatment, seven days after admission.

While on the ward, the patient still had high levels of CRP and D-dimer. Other laboratory analyses were without significant deviation from the reference ranges.

Repeated multidetector computed tomography (MDCT) imaging of the thorax, abdomen, and the lesser pelvis, on the eleventh and eighteenth day of hospitalization, revealed a persisting hematoma, 26x17x12 mm in diameter, in the left retroperitoneum, distally to the kidney. It was imbibing the left psoas muscle and could not be separated from it. The hematoma did not display signs of active bleeding and was pushing the abdominal structures medially and towards the front. There was no ascites. There were linear fibrous lesions consistent with resorptive scarring following viral pneumonia. Pleural effusion was present bilaterally, with lesser compressive areas of atelectasis.

je antibiotska terapija prema antibiogramu. Međutim, trećeg dana lečenja u našoj ustanovi javljaju se prolivaste stolice i izolovan je *Clostridium difficile*. Antibiotska terapija je korigovana. Započeta je ciljana peroralna terapija po nacionalnom vodiču za lečenje bakterije *Clostridium difficile*, vankomicinom i metronidazolom.

Laboratorijske analize su bile u postepenom poboljšanju, a nakon transfuzije krvi i derivata došlo je i do normalizacije krvne slike (KS), broj trombocita je bio u porastu, a vrednost D-dimera u padu, pa je šestog dana nakon intervencije uveden niskomolekularni heparin (engl. *low molecular weight heparin – LMWH*) u terapijskoj dozi. Bolesnik je bio na kombinovanoj enteralnoj hiperproteinskoj i parenteralnoj ishrani. Elektrolitno i metabolički je bio iskorigovan, i zadovoljavajuće glikoregulacije. Sa bolesnikom je sproveden rani rehabilitacioni tretman uz kinezitejp za velike podlive abdomena i nogu nakon retroperitonealnog hematoma. U ovoj fazi je počeo da ima fleksiju i ekstenziju u kuku i kolenu, što ranije nije imao, zbog velikog otoka ekstremiteta. Nastavljeno je sa vežbama na nivou postelje i vertikalizacijom. U stabilnom opštem stanju, a radi nastavka lečenja, bolesnik je preveden na odeljenje hirurgije, sedam dana od prijema.

Na odeljenju su se održavale povišene vrednosti CRP-a i D-dimera. Ostale laboratorijske analize su bile bez značajnih odstupanja od referentnih vrednosti.

Na ponovljenom MDCT (engl. *multidetector computed tomography*) snimanju toraksa, abdomena i male karlice, jedanaestog i osamnaestog dana hospitalizacije, i dalje je u levom retroperitoneumu, distalno od bregu, perzistirao hematoma, dijametra 26x17x12 mm, koji je imbibirao levi mišić psoas, i koji se nije mogao odvojiti od istog. Hematom je bio bez znakova aktivnog krvavljenja i potiskivao je abdominalne strukture ka medijalno i napred. Nije bilo ascitesa. U plućima su bile prisutne linearne fibrozne promene, koje su odgovarale resorptivnim ožiljnim promenama nakon virusne pneumonije. Obostrano je bio prisutan pleuralni izliv sa manjim kompresivnim atelektazama.

Devetnaestog dana hospitalizacije, postavljena je indikacija za hirurško lečenje. U uslovima opšte endotrahealne anestezije, urađena je sledeća planirana hirurška intervencija: Po pripremi operativnog polja učinjena je leva mini lumbotomija. Po prolasku kroz mišićni sloj naišlo se na masivni retroperitonealni hematoma koji je bio inkapsuliran. Po probijanju kapsule urađena je evakuacija velike količine koaguluma i stare krvi. Potom je plasiran dren. Operativna rana zatvorena je po anatomskim slojevima.

Postoperativni tok je protekao uredno, bez hirurških komplikacija. Rana je zarasla *per primam intentionem*, a dren izvađen. Bolesnik je otpušten na kućno

On the nineteenth day of hospitalization, indication for surgical treatment was established. The following planned surgical procedure was carried out under general endotracheal anesthesia: After the surgical field was prepared, left mini lumbotomy was carried out. After passing through the muscular layer, a massive encapsulated retroperitoneal hematoma was encountered. Upon penetration of the capsule, evacuation of a large quantity of coagulum and old blood was performed. A drain was then placed, and the surgical wound was closed by anatomical layers.

Postoperative recovery was uneventful, without surgical complications. The wound healed *per primam intentionem*, and the drain was removed. The patient was discharged to recover at home on the twenty-third day of hospitalization, in good general condition, afebrile, hemodynamically stable, and with normal bowel function.

## DISCUSSION

Although patients with severe form of COVID-19 tend to develop thrombotic complications, they can also have bleeding as a complication of the disease [3]. Coagulopathy in COVID-19 is significantly different from coagulopathy occurring in severe sepsis of other etiology. A combination of thrombocytopenia, prolonged prothrombin time (PT), and elevated D-dimer may indicate disseminated intravascular coagulopathy (DIC), although it differs from DIC seen in sepsis of other etiology. In sepsis, thrombocytopenia is more pronounced, while the level of D-dimer does not reach such high values as has been noted in COVID-19 patients. According to the International Society on Thrombosis and Haemostasis DIC score, most COVID-19 patients would not be classified as DIC [4]. What we know, at the moment, is that pulmonary thrombi in COVID-19 develop as the result of vascular damage related to viral infection and severe inflammation. This belief is substantiated by the levels of D-dimer and inflammatory markers, as well as by the elevation of multiple thrombolytic factors, such as IL-6 and antiphospholipid antibodies, in all of the patients. Autopsies of patients who had died of COVID-19 have revealed severe injury to the blood vessel endothelium, widespread thrombosis with microangiopathy and alveolar capillary microthrombi, as well as increased angiogenesis [5].

The frequency of bleeding is far lesser and is usually connected to the application of antithrombotic agents and anticoagulants. The total percentage of patients with complications of bleeding ranges from 4.8% to 8.0%, of whom approximately 3.5% had major bleeding [6]. However, Erdinc and Raina described a COVID-19 patient who developed spontaneous retroperitoneal hematoma (SRH) without receiving anticoagulant therapy [7]. The exact frequency of

lečenje dvadeset trećeg dana od prijema, u dobrom opštem stanju, afebrilan, hemodinamski stabilan i uredne digestivne funkcije.

## DISKUSIJA

Iako pacijenti sa teškom formom KOVID-19 infekcije imaju tendenciju razvoja trombotičkih komplikacija, takođe mogu imati i krvarenje kao komplikaciju bolesti [3]. Koagulopatija kod KOVID-19 infekcije značajno se razlikuje od koagulopatija koje se javljaju kod teške sepse druge etiologije. Kombinacija trombocitopenije, produženo protrombinsko vreme (engl. *prothrombin time* – PT) i povišen D-dimer mogu ukazivati na diseminovanu intravaskularnu koagulopatiju, tzv. DIC (engl. *disseminated intravascular coagulopathy* – DIC), iako se razlikuje od DIC-a viđenog kod sepse druge etiologije. Kod sepse, trombocitopenija je izraženija, a vrednost D-dimera ne dostiže tako visoke vrednosti kakve su primеćene kod pacijenata sa KOVID-19 oboljenjem. Prema DIC skorom Međunarodnog društva za trombozu i hemostazu (engl. *International Society on Thrombosis and Hemostasis*), većina pacijenata sa KOVID-19 oboljenjem ne bi bila klasifikovana kao DIC [4]. Trenutno znamo da plućni trombovi kod KOVID-19 oboljenja nastaju kao posledica vaskularnog oštećenja povezanog sa virusnom infekcijom i teškom upalom, o čemu svedoče nivoi D-dimera i inflamatornih markera, kao i povećanje višestrukih trombolitičkih faktora, kao što su IL-6 i anti-fosfolipidna antitela, kod ovih pacijenata. Autopsije pacijenata umrlih od KOVID-19 oboljenja otkrile su teške povrede endotela krvnih sudova, rasprostranjenu trombozu sa mikroangiopatijom i alveolarnim kapilarnim mikrotrombozima, kao i povećanu angiogenezu [5].

Učestalost krvarenja je daleko ređa i obično je povezana sa primenom antitrombotičkih agenasa i anti-koagulacije. Ukupan udeo pacijenata sa komplikacijama krvarenja kreće se od 4,8% do 8,0%, od kojih je oko 3,5% imalo veliko krvarenje [6]. Međutim, Erdinc i Raina su opisali pacijenta sa KOVID-19 infekcijom kod kojeg je nastao spontani retroperitonealni hematom (SRH) bez primene antikoagulantne terapije [7]. Precizna učestalost spontanih retroperitonealnih hematoma kod pacijenata sa KOVID-19 oboljenjem ostaje nejasna. Na početku je prijavljiv manji broj pacijenata – 3,8 slučajeva na 1.000 prijema u jedinice intenzivnog lečenja (JIL) [8]. Dok su italijanski autori, učesnici *Recovery* studije, prijavili 7,6 slučajeva na 1.000 hospitalizacija [9]. S obzirom na visoku stopu smrtnosti, lekari bi trebalo da pomno obrate pažnju na prve znake bolesti, pre svega na trombocitopeniju (broj trombocita <150×10<sup>3</sup> ćelija/mL) i na povišen nivo D-dimera (>2,5 mg/mL). Praćenje dejstva antikoagulanasa je imperativ za smanjenje rizika od hemoragičnih događaja [10]. Faktori

spontaneous retroperitoneal hematomas in COVID-19 patients remains unclear. Initially, a small number of patients was reported – 3.8 cases per 1,000 admissions to intensive care units (ICU) [8]. While Italian authors, participants in the *Recovery* study, reported 7.6 cases per 1,000 hospitalizations [9]. Bearing in mind the high mortality rate, doctors should closely monitor for first signs of illness, primarily for thrombocytopenia (platelet count <150×10<sup>3</sup> cells/mL) and for elevated D-dimer levels (>2.5 mg/mL). Monitoring the effect of anticoagulants is imperative for decreasing the risk of hemorrhagic events [10]. Risk factors for spontaneous retroperitoneal hematoma are as follows: anticoagulant therapy, older age, obesity, underlying comorbidities – most commonly hypertension and *diabetes mellitus*, as well as hemodialysis. Our patient had multiple risk factors – age (65 years); the fact that due to the underlying comorbidity he was on standard oral anticoagulant therapy; bronchopneumonia caused by COVID-19; therapeutic dosage of LMWH; bacterial intrahospital superinfection, infection caused by *Clostridium difficile*.

While the exact pathogenesis and pathophysiology of retroperitoneal bleeding is unknown, it is assumed retroperitoneal microvascular atherosclerosis may increase susceptibility to rupture, with the involvement of large blood vessels. Anticoagulant therapy and microtraumas, such as coughing and vomiting, can also lead to retroperitoneal bleeding [11]. The SARS-CoV-2 itself has an affinity for the ACE2 receptor in endothelial cells, which may directly damage blood vessels and cause bleeding. Conversely, dysregulation of the renin-angiotensin-aldosterone system, may contribute to elevated blood pressure, causing hemorrhagic events. The psoas muscle can accumulate up to ten times its own volume, which is clinically significant, as patients may lose a large volume of blood without this being noticed, unless laboratory analyses are performed and monitored regularly, and physical examinations are carried out routinely. Clinically, retroperitoneal bleeding can manifest as hypotension, abdominal pain, or a drop in the hemoglobin level [12,13]. Our patient was hypotensive, tachycardic, he was complaining of pain in the left lumbar region, where a large hematoma was visible. The dominant findings in his blood work were, as follows: anemia, with a drop in the hemoglobin (Hb) level to 81 g/L; thrombocytopenia, amounting to 75×10<sup>9</sup>/L; and a high level of D-dimer, amounting to 1,324 ng/L (cut-off – 500 ng/L).

MDCT imaging of the abdomen and the lesser pelvis is an initial diagnostic procedure applied when there is suspicion of retroperitoneal bleeding. Initial treatment begins with discontinuing anticoagulant therapy, performing transfusion of blood and blood

rizika za spontani retroperitonealni hematom su: anti-koagulantna terapija, starije životno doba, gojaznost, prateći komorbiditeti – najčešće hipertenzija i *diabetes mellitus*, kao i hemodijaliza. Kod našeg pacijenta je bilo zastupljeno više faktora rizika – godine starosti (65 godina); činjenica da je zbog pratećeg komorbiditeta bio na redovnoj oralnoj antikoagulantnoj terapiji; bronhopneumonija izazvana KOVID-19 oboljenjem; LMWH u terapijskoj dozi; bakterijska intrahospitalna superinfekcija, infekcija izazvana *Clostridium-om difficile*.

Dok je precizna patogeneza i patofiziologija retroperitonealnog krvarenja nepoznata, pretpostavlja se da bi retroperitonealna mikrovaskularna ateroskleroza mogla da poveća osetljivost na rupturu, uz zahvatanje velikih krvnih sudova. Antikoagulacija i mikrotraume, kao što su kašalj ili povraćanje, takođe mogu dovesti do retroperitonealnog krvarenja [11]. Sam virus SARS-CoV-2 ima afinitet za ACE2 receptor na endotelnim ćelijama, što može direktno da ošteti krvne sudove i izazove krvarenje. Nasuprot tome, disregulacija sistema renin-angiotenzin-aldosteron, može doprineti povećanju krvnog pritiska, izazivajući hemoragične događaje. Psoas mišić može da akumulira i do deset puta veći volumen od sopstvenog, što je klinički značajno, jer pacijenti mogu da izgube veliki volumen krvi a da se to ne primeti, ukoliko se redovno ne prate laboratorijske analize i ne obavlja fizikalni pregled. Klinički se retroperitonealno krvarenje može manifestovati hipotenzijom, bolom u stomaku ili padom hemoglobina [12,13]. Naš pacijent je bio hipotenzivan, tahikardičan, žalio se na bol u levoj slabinskoj regiji, gde je bio vidljiv veliki hematom. U laboratorijskim analizama dominirale su: anemija, sa padom vrednosti hemoglobina (Hb) na 81 g/L; trombocitopenija od  $75 \times 10^9/L$ ; i visoka vrednost D-dimera od 1.324 ng/L (gornja granica – 500 ng/L).

MDCT abdomena i male karlice je inicijalna dijagnostička procedura kod sumnje na retroperitonealno krvarenje. Inicijalni tretman počinje obustavljanjem antikoagulantne terapije, transfuzijom krvi i krvnih derivata, nadoknadom volumena infuzionim rastvorima, i drugim merama hemodinamske potpore i oksigenoterapije. Hemodinamski nestabilni pacijenti na antikoagulantnoj terapiji sa nepredvidivim velikim hematomima mekih tkiva mogu se lečiti arterijskom embolizacijom, jer je to minimalno invazivna procedura sa brzim terapijskim efektom, u poređenju sa hirurškim lečenjem. Kada se nađe aktivno krvarenje u psoasu, opravdana je arterijska embolizacija treće i četvrte lumbalne arterije, što predstavlja tehnički izazov jer zahteva selektivnu kateterizaciju arterije, embolizaciju, kao i procenu nakon embolizacije, da bi se potvrdila uspešnost intervencije [14]. Kod našeg pacijenta uspešno je urađena embolizacija lumbalnih arterija levo.

derivatives, providing blood volume supplementation through solutions administered via infusion therapy, and other measures of hemodynamic support and oxygenotherapy. Hemodynamically unstable patients on anticoagulant therapy with unpredictable large hematomas of the soft tissues may be treated by arterial embolization, as this is a minimally invasive procedure with rapid therapeutic effect, as compared to surgical treatment. When active bleeding is discovered in the psoas muscle, arterial embolization of the third and fourth lumbar artery is justified, which poses a technical challenge, as it requires selective catheterization of the artery, embolization, as well as assessment after embolization, in order to confirm the success of the procedure [14]. In our patient, embolization of lumbar arteries on the left was successfully performed.

Analysis of available literature shows that precedence is given to conservative treatment, in combination with the interventional radiological procedure of the embolization of damaged blood vessels. It seems that surgery is indicated when the patient remains unstable, despite the application of measures of intensive reanimation, in cases when interventional radiology is not successful or is not available, or in case of the development of compartment syndrome [15]. In our case, after radiological therapy and conservative treatment, the patient was operated on with the application of mini-laparotomy for the purpose of evacuating a necrotizing hematoma, which could not be reabsorbed spontaneously.

## CONCLUSION

The application of anticoagulant therapy may cause severe hemorrhagic complications in COVID-19 patients. Monitoring the effect of anticoagulant therapy, especially in patients with risk factors, early diagnostics, as well as timely treatment of spontaneous retroperitoneal hematomas, is imperative for decreasing mortality from this severe complication in COVID-19 patients.

## LIST OF ABBREVIATIONS AND ACRONYMS

SARS-CoV-2 - severe acute respiratory syndrome coronavirus 2

COVID-19 - coronavirus disease of 2019

DIC – disseminated intravascular coagulation

CT – computerized tomography

SpO<sub>2</sub> – oxygen saturation of the patient's blood

CVC – central venous catheter

ROTEM – rotational thromboelastometry

LMWH – low molecular weight heparin

CRP – C-reactive protein

**Conflict of interest:** None declared



Pretragom dostupne literature, uočava se da primat u lečenju ima konzervativni tretman u kombinaciji sa interventnom radiološkom procedurom embolizacije oštećenih krvnih sudova. Čini se da je operacija indikovana kada pacijent ostaje nestabilan uprkos preduzetim merama intenzivne reanimacije, ako interventna radiologija nije uspešna ili je nedostupna, ili u slučaju razvoja kompartment sindroma [15]. U našem slučaju, bolesnik je, nakon radiološke intervencije i konzervativnog lečenja, operisan mini laparotomijom, u cilju evakuacije nekrotizirajućeg hematoma, koji nije mogao spontano da se resorbuje.

## ZAKLJUČAK

Primena antikoagulanasa može izazvati teške hemoragijske komplikacije kod pacijenata sa KOVID-19 oboljenjem. Praćenje dejstva antikoagulantne terapije, naročito kod pacijenata sa prisutnim faktorima rizika, rana dijagnostika, kao i blagovremena terapija spontanih retroperitonealnih hematoma, predstavlja imperativ za smanjenje mortaliteta od ove teške komplikacije pacijenata sa KOVID-19 infekcijom.

## SPISAK SKRAĆENICA

SARS-KoV-2 - ozbiljni akutni respiratorni sindrom korona virus 2 (engl. *severe acute respiratory syndrome coronavirus 2 - SARS-CoV-2*)

KOVID-19 – bolest izazvana koronavirusom 2019 (engl. *coronavirus disease of 2019 – COVID-19*)

DIC – diseminovana intravaskularna koagulopatija (engl. *disseminated intravascular coagulopathy*)

CT – kompjuterizovana tomografija (engl. *computerized tomography*)

SpO<sub>2</sub> - % zasićenja hemoglobina kiseonikom

CVK – centralni venski kateter

ROTEM - rotacijska tromboelastografija

LMWH – niskomolekularni heparin (engl. *low molecular weight heparin*)

CRP – C-reaktivni protein

**Sukob interesa:** Nije prijavljen.

## LITERATURA / REFERENCES

- Scialpi M, Russo P, Piane E, Gallo E, Scalera GB. First case of retroperitoneal hematoma in COVID-19. *Turk J Urol.* 2020 Sep;46(5):407-9. doi: 10.5152/tud.2020.20302.
- Malas MB, Naazie IN, Elsayed N, Mathlouthi A, Marmor R, Clary B. Thromboembolism risk of COVID-19 is high and associated with a higher risk of mortality: A systematic review and meta-analysis. *EClinicalMedicine.* 2020 Dec;29:100639. doi: 10.1016/j.eclinm.2020.100639.
- Al-Samkari H, Karp Leaf RS, Dzik WH, Carlson JCT, Fogerty AE, Waheed A, et al. COVID-19 and coagulation: bleeding and thrombotic manifestations of SARS-CoV-2 infection. *Blood.* 2020 Jul 23;136(4):489-500. doi: 10.1182/blood.202006520.
- Levi M, Thachil J, Iba T, Levy JH. Coagulation abnormalities and thrombosis in patients with COVID-19. *Lancet Haematol.* 2020 Jun;7(6):e438-e40. doi: 10.1016/S2352-3026(20)30145-9.
- Ackermann M, Verleden SE, Kuehnel M, Haverich A, Welte T, Laenger F, et al. Pulmonary Vascular Endothelialitis, Thrombosis, and Angiogenesis in Covid-19. *N Engl J Med.* 2020 Jul 9;383(2):120-8. doi: 10.1056/NEJMoa2015432.
- Shah A, Donovan K, McHugh A, Pandey M, Aaron L, Bradbury CA, et al. Thrombotic and haemorrhagic complications in critically ill patients with COVID-19: a multicentre observational study. *Crit Care.* 2020 Sep 18;24(1):561. doi: 10.1186/s13054-020-03260-3.
- Erdinc B, Raina JS. Spontaneous Retroperitoneal Bleed Coincided With Massive Acute Deep Vein Thrombosis as Initial Presentation of COVID-19. *Cureus.* 2020 Aug 15;12(8):e9772. doi: 10.7759/cureus.9772.
- Artzner T, Clere-Jehl R, Schenck M, Greget M, Merdji H, De Marini P, et al. Spontaneous ilio-psoas hematomas complicating intensive care unit hospitalizations. *PLoS One.* 2019 Feb 22;14(2):e0211680. doi: 10.1371/journal.pone.0211680.
- Vergori A, Pianura E, Lorenzini P, D'Abramo A, Di Stefano F, Grisetti S, et al.; ReCOVeRI Study Group. Spontaneous ilio-psoas haematomas (IPHs): a warning for COVID-19 inpatients. *Ann Med.* 2021 Dec;53(1):295-301. doi: 10.1080/07853890.2021.1875498.
- Patel I, Akoluk A, Douedi S, Upadhyaya V, Mazahir U, Costanzo E, et al. Life-Threatening Psoas Hematoma due to Retroperitoneal Hemorrhage in a COVID-19 Patient on Enoxaparin Treated with Arterial Embolization: A Case Report. *J Clin Med Res.* 2020 Jul;12(7):458-61. doi: 10.14740/jocmr4256.
- Llitjos JF, Daviaud F, Grimaldi D, Legriel S, Georges JL, Guerot E, et al. Ilio-psoas hematoma in the intensive care unit: a multicentric study. *Ann Intensive Care.* 2016 Dec;6(1):8. doi: 10.1186/s13613-016-0106-z.
- Surani S, Estement B, Manchandan S, Sudhakaran S, Varon J. Spontaneous extraperitoneal lumbar artery hemorrhage. *J Emerg Med.* 2011 Jun;40(6):e111-4. doi: 10.1016/j.jemermed.2008.01.029.
- Qanadli SD, El Hajjam M, Mignon F, Bruckert F, Chagnon S, Lacombe P. Life-threatening spontaneous psoas haematoma treated by transcatheter arterial embolization. *Eur Radiol.* 1999;9(6):1231-4. doi: 10.1007/s003300050824.
- Amole AO, Kathuria MK, Ozkan OS, Gill AS, Ozkan EO. Lumbar artery laceration with retroperitoneal hematoma after placement of a G-2 inferior vena cava filter. *Cardiovasc Intervent Radiol.* 2008 Nov-Dec;31(6):1257-9. doi: 10.1007/s00270-008-9365-x.
- Chan YC, Morales JP, Reidy JF, Taylor PR. Management of spontaneous and iatrogenic retroperitoneal haemorrhage: conservative management, endovascular intervention or open surgery? *Int J Clin Pract.* 2008 Oct;62(10):1604-13. doi: 10.1111/j.1742-1241.2007.01494.x.