

# ZNAČAJ ADENOZIN DEAMINAZE U DIJAGNOSTIKOVANJU TUBERKULOZNOG PLEURITISA

PREGLEDNI RAD

REVIEW ARTICLE

## SIGNIFICANCE OF ADENOSINE DEAMINASE IN DIAGNOSING TUBERCULOUS PLEURISY

Jelena Janković<sup>1,2</sup>, Branislav Ilić<sup>1,2</sup>, Aleksandar Jandrić<sup>1</sup>

<sup>1</sup> Univerzitetski klinički centar Srbije, Klinika za pulmologiju, Beograd, Srbija

<sup>1</sup> University Clinical Center of Serbia, Clinic for Pulmonology, Belgrade, Serbia

<sup>2</sup> Univerzitet u Beogradu, Medicinski fakultet, Beograd, Srbija

<sup>2</sup> University of Belgrade, Faculty of Medicine, Belgrade, Serbia

### SAŽETAK

Tuberkulozni pleuritis (TP) je jedan od najčešćih ekstrapulmonalnih oblika tuberkuloze. Tuberkulozni pleuritis nastaje kada se *Mycobacterium tuberculosis* antigen oslobodi iz rupturiranog kazeoznog fokusa u pleuralni prostor i izazove hiperinflamatorni odgovor sa brzim prilivom limfocita.

Direktna mikroskopija za acido-alkoholo rezistentan bacil (AFB), kulture i patohistološki nalaz biopsije kod većine pacijenata su pozitivni samo kod manje od 10% uzoraka. Za dobijanje rezultata kulture potrebno je oko 6-8 nedelja, što odlaže konačnu dijagnozu. Problem nastaje i u diferencijaciji izliva sa limfocitnom predominacijom. Adenozin deaminaza (ADA) je biohemijski marker visoke senzitivnosti i specifičnosti i smatra se zlatnim standardom biomarkera u dijagnostici TP. Koristeći algoritam za vrednosti ADA više ili niže od 40 U/L možemo razlikovati ovaj tip izliva od drugih.

ADA je brz, efikasan i ekonomičan način za razjašnjavanje etiologije pleuralnog izliva kao što je tuberkulozni pleuritis i odgovora na lečenje u periodu praćenja.

**Ključne reči:** adenozin deaminaza, biomarkeri, pleuralni izliv, tuberkuloza

### ABSTRACT

Tuberculous pleurisy (TP) is one of the most common extra-pulmonary tuberculosis forms. Tuberculous pleurisy occurs when *Mycobacterium tuberculosis* antigen is released from a ruptured caseous focus into the pleural space causing hyperinflammatory response with a rapid influx of lymphocytes.

Acid-fast bacilli (AFB) staining, cultures and pathohistological biopsy finding are positive in most patients only in less than 10% of samples. Culture results take about 6-8 weeks which delays the diagnosis. A problem also occurs in the differentiation of effusions with lymphocytic predominance. Adenosine deaminase (ADA) is a biochemical marker with high sensitivity and specificity and is considered a gold standard within biomarkers when it comes to diagnosing TP. Using an algorithm for the values of ADA above or below 40 U/L we can distinguish this type of effusion from other types.

ADA in pleural punctate is a fast, efficient, and economical way for clarifying the etiology of a pleural effusion such as tuberculous pleurisy and treatment response during the follow up period.

**Keywords:** adenosine deaminase, biomarkers, pleural effusion, tuberculosis

Autor za korespondenciju:

Jelena Janković

Klinika za pulmologiju, Univerzitetški klinički centar Srbije

Koste Todorovića 26, 11000 Beograd, Srbija

Elektronska adresa: jjelena1984@gmail.com

Corresponding author:

Jelena Janković

Clinic for Pulmonology, University Clinical Center of Serbia

26 Koste Todorovića Street, 11000 Belgrade, Serbia

E-mail: jjelena1984@gmail.com

**Primljeno • Received:** April 18 2023;

**Revidirano • Revised:** June 2, 2023;

**Prihvaćeno • Accepted:** July 17, 2023;

**Online first:** September 25, 2023

DOI: 10.5937/smcl4-44046

## UVOD

Kada je reč o infektivnim bolestima, tuberkuloza (TBC) je bila vodeći uzrok smrtnosti u 2019. godini [1,2]. Tuberkuloza i dalje predstavlja ogroman problem u savremenom svetu – iako smo bili na korak od njenog iskorenjivanja, stopa morbiditeta i stopa mortaliteta nisu opale prema očekivanjima. Obrasci bolesti su se promenili, tako da TB može, ali i ne mora biti praćena respiratornim simptomima, a postoji i veća incidenca vanplućne tuberkuloze [1]. Ekstrapulmonalni oblik TBC sreće se kod oko 15-25% svih pacijenata obolelih od tuberkuloze. Limfadenitis i tuberkulozni pleuritis (TP) su dva najčešća ekstrapulmonalna oblika tuberkuloze [1,2]. Ekstrapulmonalni oblici infekcije takođe zahvataju i koštano-zglobni sistem, centralni nervni system, oči, gastrointestinalni trakt, ali i bilo koji drugi organ [3].

## TUBERKULOZNI PLEURITIS

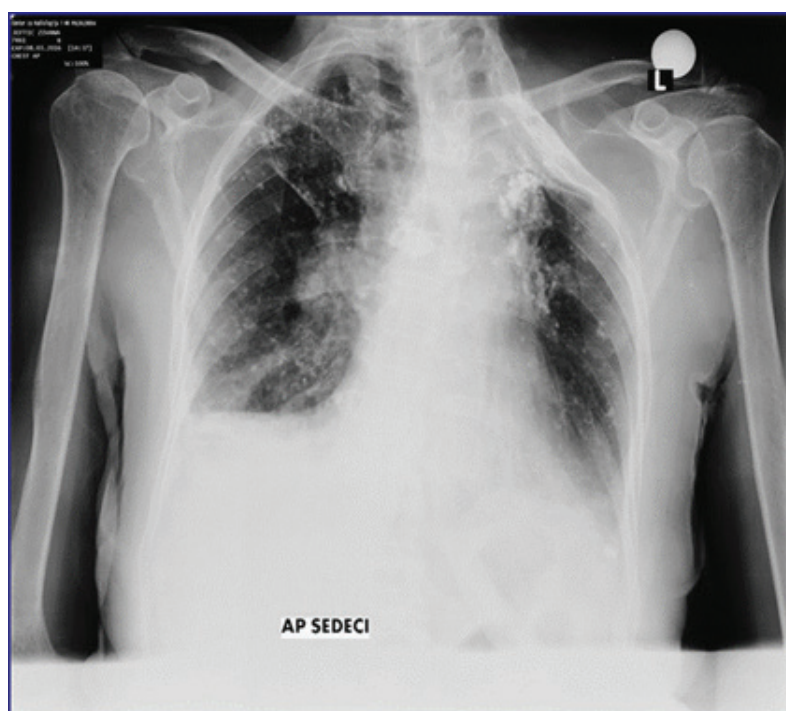
Do tuberkuloznog pleuritisa dolazi kada se *Mycobacterium tuberculosis* antigen oslobodi iz rupturiranog kazeoznog fokusa u pleuralni prostor [4]. Ovaj antigen izaziva hiperinflamatorni odgovor sa brzim prilivom neutrofila, praćenim brzim prilivom makrofaga i limfocita. Iz tog razloga, ovakav izliv se smatra eksudativnim pleuralnim izlivom sa limfocitnom predominacijom [4]. Problem može predstavljati maligni pleuralni izliv koji je takođe izliv sa limfocitnom predominacijom. Ostale karakteristike ovog tipa izliva mogu biti slične onima koje se sreću kod drugih tipova pleuritisa. Pleuralna

## INTRODUCTION

When it comes to infectious diseases, tuberculosis (TB) was the leading cause of death in 2019 [1,2]. Tuberculosis remains a major problem in the modern world – although its eradication was imminent, morbidity and mortality rates have not decreased as predicted. Disease patterns have changed, so TB may or may not be accompanied by pulmonary symptoms, and there is a higher incidence of extra-pulmonary TB as well [1]. An extra-pulmonary form of tuberculosis is found in about 15-25% of all patients with tuberculosis. Lymphadenitis and tuberculous pleurisy (TP) are the two most common extra-pulmonary forms [1,2]. Extra-pulmonary forms of infection also affect osteoarticular areas, the central nervous system, eyes, the gastrointestinal tract, and generally any organ [3].

## TUBERCULOUS PLEURISY

Tuberculous pleurisy occurs when *Mycobacterium tuberculosis* antigen is released from a ruptured caseous focus into the pleural space [4]. This antigen causes a hyperinflammatory response with a rapid influx of neutrophils, followed by an influx of macrophages and lymphocytes. Therefore, this effusion is of lymphocyte-predominant exudative pleural type [4]. There may be a problem with malignant pleural effusion which is also lymphocyte-predominant effusion. Other characteristics of this type of effusion can be like in other pleurisy types. The TB fluid is usually clear but may be opalescent as in case of bacterial pleurisy



Slika 1. Rentgenski snimak tuberkuloznog pleuritisa

Figure 1. Tuberculous effusion in chest X-ray radiography

tečnost je obično bistra, ali može biti i zamućena kao u slučaju bakterijskog pleuritisa praćenog parapneumoničnim izlivom sa pneumonijom [5]. Na osnovu C-reaktivnog proteina, amilaze ili moždanog natriuretskog peptida iz uzorka pleuralnog izliva mogu se diferencirati različiti tipovi izliva [6,7]. Uz antibiotsku terapiju (fluorohinoloni), izliv može parcijalno ili potpuno regresirati u slučaju bakterijskog parapneumoničnog izliva, što odlaže postavljanje prave dijagnoze do trenutka dok se izliv ponovo ne javi (Slika 1).

Usled nedostatka blagovremene dijagnoze i lečenja, u malom broju slučajeva mogu se javiti ozbiljne komplikacije, kao što su empijem, bronhopleuralne fistule, fibrotoraks, ili bronhijalna stenozna [1,8]. U 90% slučajeva, izliv je obično eksudat sa limfocitnom predominacijom, ali maligni izliv takođe može da ima ovakve karakteristike [6,7]. Potreban nam je biomarker pomoću kojeg bismo mogli da razlikujemo maligne tipove tuberkuloznog pleuralnog izliva od ostalih pleuralnih izliva.

## INVAZIVNA I MIKROBIOLOŠKA DIJAGNOSTIKA TUBERKULOZNOG PLEURITISA

Dijagnostikovanje TBC kod pacijenata sa tuberkuloznim pleuritisom bez istovremenog postojanja perifernih plućnih lezija predstavlja izazov, jer je kod njih rezultat bakteriološkog pregleda iskašljaja (sputuma) negativan. Kod mnogih ovakvih pacijenata, pregled razmaza sputuma metodom bojenja po Cil-Nilsenu (Ziehl-Neelsen) je negativan i zato bolji pristup dijagnostikovanju predstavlja torakocenteza. Dijagnoza tuberkuloznog pleuritisa obuhvata sledeće kriterijume: direktna mikroskopija za acido-alkoholo rezistentne bacile (AARB) ili kultivisanje na Levenštajn-Jensen (Löwenstein-Jensen) podlogama, uzimanje uzorka pleure putem biopsije i patohistološki nalaza (otkrivanje promena nalik na granulom u uzorcima dobijenim slepom biopsijom pleure i isključivanje nastanka pleuritisa usled nekog drugog razloga) [9]. Korišćenje tečne podloge uz inokulaciju pleuralne tečnosti može dati veći doprinos i brže rezultate u poređenju sa konvencionalnim metodama [9]. Patohistološki pregled i mikobakterijska kultura dobijena biopsijom iz pleuralnog tkiva predstavljaju zlatni standard u dijagnostici. Slep iglena biopsija pleure smatra se najsenzitivnijim testom za tuberkulozni pleuritis [10]. Diakon i saradnici sprovedli su komparativnu studiju i dobili zanimljive rezultate: senzitivnost patohistološkog nalaza, kultura, i kombinacije patohistološkog nalaza i kultura bila je, redom, 66%, 48%, i 79% kada je u pitanju slepa biopsija iglom, a 100%, 76%, i 100%, redom, kada je reč o torakoskopiji. Torakoskopija omogućava bolji pregled cele pleure, kao i ciljanu biopsiju, adheziozisu, i drenažu tuberkuloznog pleuritisa [10].

in para-pneumonic effusion with pneumonia [5]. C-reactive protein, amylases or natriuretic brain peptide in pleural effusion sample can be used to differentiate between the effusion types [6,7]. With antibiotic therapy (fluoroquinolones), effusion can be partial, or it resolves completely as in case of bacterial para-pneumonic disorder delaying the right diagnosis until the effusion reappears (Figure 1).

Lack of timely diagnosis and treatment can develop severe complications in a small percent of cases, such as empyema, bronchopleural fistulas, fibrothorax, or bronchial stenosis [1,8]. Effusion is almost always an exudate, with lymphocytic predominance in about 90% of cases, but malignant effusion can have these characteristics as well [6,7]. We need a biomarker, which can differentiate between the malignant form of tuberculous pleural effusion and other pleural effusions.

## INVASIVE AND MICROBIOLOGICAL DIAGNOSIS OF TUBERCULOUS PLEURISY

Diagnosis of TB is challenging in patients with tuberculous pleurisy without a coexisting parenchymal lesion as they are sputum negative. In many of these cases, sputum smear through Ziehl-Neelsen staining can be negative. Therefore, a better approach to diagnosing is thoracentesis. Diagnosis of TP should meet the following criteria: acid-fast bacilli (AFB) staining or Löwenstein-Jensen cultures, pleural biopsy culture, and histology (granuloma-like changes in pleural biopsy samples and the exclusion of pleurisy due to other causes) [9]. The use of liquid culture media with inoculation of the pleural fluid can provide higher yields and faster results in comparison with conventional methods [9]. Histological analysis and mycobacterial culture from the pleural tissue obtained by biopsy have been the gold standard in diagnostics. Blind closed pleural biopsy is the most sensitive diagnostic test for tuberculous pleurisy [10]. Diakon et al. conducted a direct comparative study and obtained interesting results: the sensitivity of histology, culture and the combination of histology and culture was 66%, 48%, and 79%, respectively, for closed-needle biopsy and 100%, 76%, and 100%, respectively, for thoracoscopy. It helps visualize the entire pleural surface and allows target biopsy, adhesionolysis, and drainage of TP [10].

All these analyses have limitations. The yield of *M. tuberculosis* is shown to be very low in tuberculous pleural effusions [11]. AFB staining and cultures from most patients are positive in only 10% of cases [12]. Culture results take about 6-8 weeks which delays the diagnosis and the right treatment. The problem is that

Sve navedene analize imaju ograničenja. Pokazalo se da je količina *M. tuberculosis* veoma niska u tuberkuloznom pleuritisu [11]. Direktna mikroskopija AARB i kulture su uglavnom pozitivni u svega 10% slučajeva [12]. Rezultati kultivacija dostupni su tek nakon 6-8 nedelja što odlaže postavljanje dijagnoze i započinjanje adekvatnog lečenja. Problem je u tome što je manje od četvrtine svih rezultata pozitivno, pa je zbog toga tečna podloga bolje rešenje [13]. Ograničenje torakocenteze je mali uzorak za dijagnostikovanje, pa se takav uzorak ni ne može smatrati tipičnim predstavnikom cele količine pleuralne tečnosti i njenih osobina. Biopsija pleure predstavlja invazivan pristup i rezultat je uglavnom negativan jer je u pitanju slepa iglena biopsija [14]. Postoji još invazivniji pristup - pleuroskopija koja se izvodi u totalnoj anesteziji ili VATS (video asistirana toraskopska hirurgija) koji ima dosta kontraindikacija (komorbiditeti, godine starosti) i mogućih komplikacija. Senzitivnost i specifičnost su mnogo bolji, preko 90% i 100% [13]. Negativan razmaz sputuma na acido-alkoholo rezistentni bacil, odsustvo granuloma u patohistološkom nalazu biopsije i nemogućnost kultivisanja *Mycobacterium tuberculosis* ne isključuju nužno dijagnozu.

Zbog svega navedenog, teško je postaviti dijagnozu tuberkuloznog pleuritisa i potrebno je dosta vremena da bi se došlo do dijagnoze i započelo lečenje. Cilj ovog rada je razjašnjenje dijagnoze tuberkuloznog pleuritisa upotrebom visokoosetljivog i specifičnog biomarkera, što zapravo predstavlja neinvazivan pristup koji daje odlične rezultate.

## ADENOZIN DEAMINAZA KAO BIOMARKER TUBERKULOZNOG PLEURITISA

Biohemijski marker za dijagnostikovanje tuberkuloznog pleuritisa je adenzin deminaza (ADA). Agarwal i saradnici ažurirali su vrednosti za osetljivost (0.92) i specifičnost (0.90) ADA zaključivši da je reč o zlatnom standardu biomarkera za otkrivanje pleuralne TBC među odraslima, što potvrđuje i više od 170 publikacija [15]. Sistemski pregled i meta-analiza pokazali su da je ovaj biomarker pogodan za otkrivanje tuberkuloznog pleuritisa kod pedijatrijske populacije [16]. Nivo ADA u pleuralnom izlivu može biti niži kod starijih pacijenata, kritično obolelih, ili onih koji imaju multiorgansko oštećenje [15].

ADA je enzim koji se sintetiše u više ćelija: mononuklearnim ćelijama, limfocitima, neutrofilima. Postoje dva različita tipa ADA biomarkera: ADA1 koji je ubikvitaran i nalazi se u mnogim ćelijama, i ADA2 koji sintetiše monociti/makrofagi i koji je odgovoran za tuberkulozni pleuritis [5]. Mikobakterijski antigeni u pleuralnoj tečnosti stimulišu Th1-limfocite. ADA je enzim T

less than a quarter of all results are positive, so fluid culture is a better solution [13]. Limitation of thoracentesis is a small sample for diagnosis, so the sample cannot represent the entire amount of pleural fluid and its characteristics. Pleural biopsy approach is invasive and usually negative because it is a blind closed biopsy [14]. A more invasive approach is pleuroscopy in total sedation or VATS (video assisted thoracoscopic surgery), which has many contraindications (such as comorbidities or age) and complications. Sensitivity and specificity are much better, over 90% and 100% [13]. A negative smear for acid-fast bacilli, a lack of granulomas in histopathology, and a failure to culture *Mycobacterium tuberculosis* do not exclude the diagnosis itself.

Because of all the above mentioned, it is difficult to diagnose TP, and it takes a lot of time to establish the right diagnosis and start the treatment. The aim of this paper is to clarify the diagnosis of TP using a highly sensitive and specific biomarker, which is practically a non-invasive approach with excellent results.

## ADENOSINE DEAMINASE AS A BIOMARKER OF TUBERCULOUS PLEURISY

The biochemical marker for diagnosing TP is adenosine deaminase (ADA). Aggarwal et al. updated the sensitivity (0.92) and specificity (0.90) of ADA concluding it was a gold standard within biomarkers for detecting pleural TB among adults, which has been supported by more than 170 publications [15]. A systematic review and meta-analysis showed that this biomarker was convenient for detecting TP in pediatric population [16]. The level of ADA in the pleural effusion can be lower in elderly patients, the critically ill or those with multi-organ dysfunction [15].

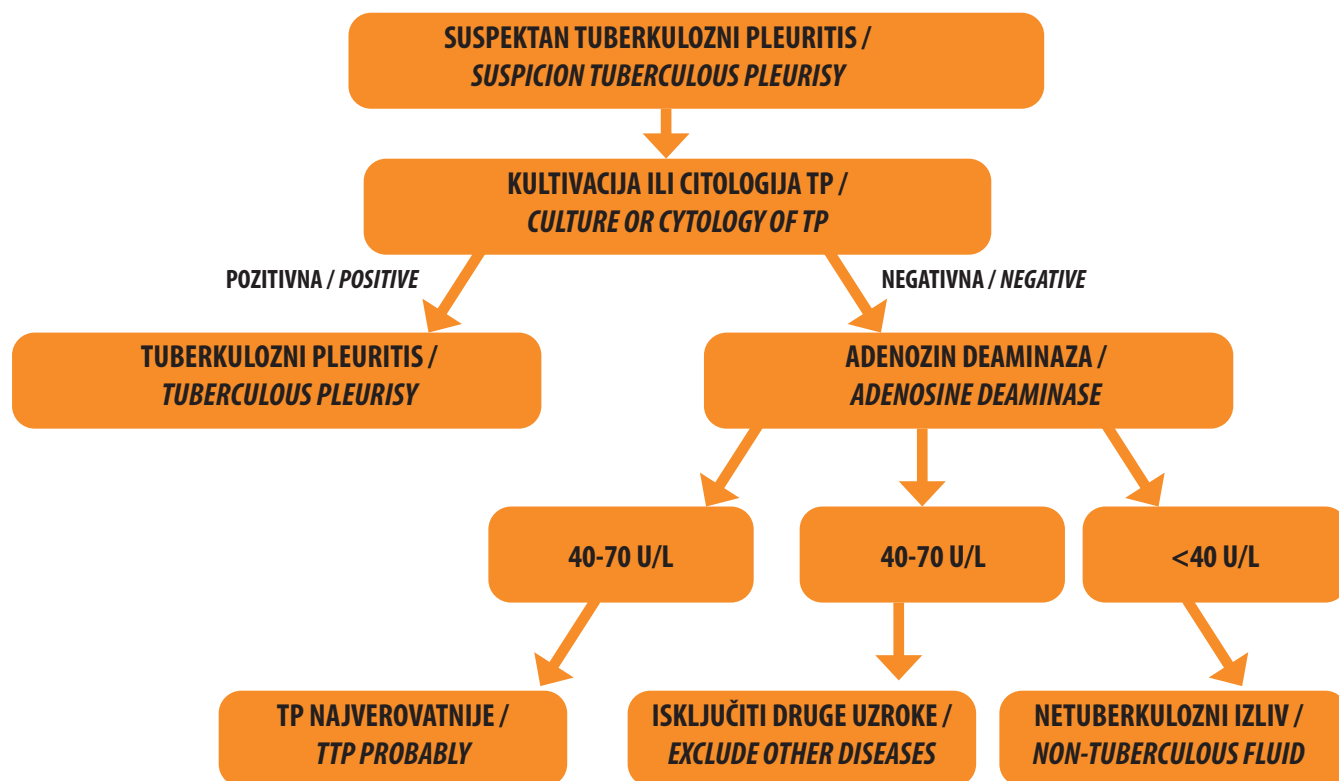
ADA is an enzyme synthesized by many cells: mononuclear cells, lymphocytes, neutrophils. There are two different types of ADA biomarker: ADA1 that is ubiquitous and can be found in many cells, and ADA2 that is produced by monocytes/macrophages and is responsible for tuberculous pleuritis [5]. Mycobacterial antigens in pleural fluid stimulate Th1 lymphocytes. ADA is a T lymphocyte enzyme that catalyzes adenosine into inosine and due to this the amount of this enzyme is increased in a lymphocyte-rich exudate [14,16]. According to numerous studies, the most accepted cutoff value for pleural ADA is 40 U/L [9]. About 30% of para-pneumonic effusions and 70% of empyema cases have ADA levels above 40 U/L. We can distinguish between these two effusions with neutrophil or lymphocyte predominant cytology. High ADA levels have also been reported in patients with lymphomas, but this effusion has extremely high

limfocita koji konvertuje adenzin u inozin i zbog toga je količina ovog enzima veća u eksudatu bogatom limfocitima [14,16]. Prema brojnim studijama, najprihvatljivija granična vrednost pleuralnog ADA je 40 U/L [9]. Oko 30% parapneumoničnih izliva i 70% slučajeva empijema daju vrednosti ADA iznad 40 U/L. Možemo da razlikujemo ova dva tipa izliva sa neutrofilnom ili limfocitnom predominacijom. Visoke vrednosti ADA takođe su opisane kod pacijenata sa limfomom, ali takav izliv daje ekstremno visoke vrednosti ADA (>250 U/L) [6]. Kod malignog mezotelioma vrednosti ADA su uglavnom niske [17]. Ali, limfocitna predominacija može biti prisutna i kod malignog mezotelioma kao i kod drugih malignih izliva, gde drugi biomarkeri mogu poslužiti za razlikovanje ova dva tipa izliva, kao i za određivanje patohistološkog profila (karletinin ili keratin 5) [16].

Sudeći po podacima iz literature i meta-analiza, ADA2 kao izoenzim može pomoći u diferencijaciji tuberkuloznog pleuritisa od drugih vrsta pleuralnog izliva [9,18] sa većom senzitivnošću i specifičnošću u dijagnostikovanju tuberkuloznog pleuritisa. U oblastima sa visokom prevalencom TBC, pleuralne vrednosti ADA iznad 20 U/L pokazale su odličnu osetljivost i specifičnost, dok se u oblastima sa niskom prevalencom vrednosti između 40 U/L i 70 U/L mogu povezati sa brojnim lažno pozitivnim rezultatima. Iz tog razloga,

ADA values (>250 U/L) [6]. Malignant mesotheliomas usually have low ADA levels [17]. Malignant mesothelioma can have lymphocyte predomination like other malignant effusions, but other biomarkers can be used to distinguish between those two types of effusion, as well as a histological biopsy profile, such as Carletinin or Cytokeratin5 [16].

According to literature and meta-analyses, ADA2 as isoenzymes may help distinguish TP from other types of pleural effusion [9,18] with greater sensitivity and specificity in the diagnosis of TP. In high TB prevalence regions, pleural ADA values above 20 U/L showed excellent sensitivity and specificity, while in low TB prevalence regions, values between 40 U/L and 70 U/L may be associated with numerous false positives results. For that reason, some authors suggest ADA cut-off point of 70 U/L [19]. If we use established cut off values of the fluid ADA and if it is above 70 U/L with clinical presentation, the diagnosis of tuberculous pleurisy is established, and anti-tuberculous therapy can be started. If pleural fluid ADA is between 40 U/L and 70 U/L, further diagnostic procedures such as a needle biopsy or thoracoscopy should be performed. If the patient's pleural fluid ADA level is below 40 U/L, the diagnosis of tuberculosis is unlikely (Figure 2) [9]. Due to this, the level of pleural ADA is used as a part of various ratio or



Slika 2. Algoritam za dijagnostikovanje tuberkuloznog pleuritisa

Figure 2. The algorithm for diagnosing tuberculous pleurisy

neki autori predlažu da granična vrednost ADA bude 70 U/L [19]. Ukoliko koristimo utvrđene vrednosti ADA u pleuralnoj tečnosti i ukoliko su one preko 70 U/L uz postojanje kliničke slike, možemo postaviti dijagnozu tuberkuloznog pleuritisa i započeti sa antibakterijskom terapijom. Ukoliko su vrednosti ADA u pleuralnoj tečnosti između 40 i 70 U/L, potrebno je primeniti druge dijagnostičke procedure, kao što su iglena biopsija ili torakoskopija. Ako su vrednosti ADA u pleuralnoj tečnosti ispod 40 U/L, mala je verovatnoća da je u pitanju tuberkuloza (Slika 2) [9]. Zbog toga, nivo ADA u pleuralnoj tečnosti koristi se kao deo raznih sistema skorovanja i odnosa. Jedan od najčešće korišćenih odnosa je serumski LDH/ADA u pleuralnoj tečnosti (cancer ratio), gde vrednosti iznad 20 ukazuju na maligni pleuralni izliv. U oblastima sa visokom prevalencom TBC i kod pacijenata kod kojih je prisutan eksudat sa limfocitnom predominacijom uz postojanje sumnje na tuberkulozu i vrednosti ADA >40 IU/L postoji pozitivna prediktivna vrednost od 98%. ADA je najčešće korišćen test za dijagnostikovanje tuberkuloze u oblastima sa umerenom prevalencom bolesti, dok se u oblastima sa niskom prevalencijom ADA može koristiti kao test koji isključuje postojanje bolesti [18,21]. Nedostatak ovog biomarkera je u tome što ne pruža podatke o kultivaciji i tipu mikobakterioze i rezistenciji na lekove [21].

ADA takođe ima značajnu ulogu u odgovoru na lečenje tokom perioda praćenja bolesti. U jednoj prospektivnoj studiji iz Indije, autori su pokazali da bi serumski nivo ADA mogao da bude od koristi za praćenje anti-tuberkuloznog dejstva. Rezultati su pokazali postojanje značajne razlike između vrednosti ADA pre i nakon lečenja tuberkuloze ( $p < 0,001$ ) [22].

Imajući u vidu sve pomenute razloge, na Klinici za pulmologiju koristimo ADA u svakodnevnoj praksi. U pitanju je brz i jednostavan način za potvrđivanje tuberkuloznog pleuritisa kada su druge dijagnostičke procedure dale negativne rezultate. Važno je da u 21. veku ne gubimo dragoceno vreme na kultivaciju i ponavljanje pleuralne torakocenteze i biopsije pleure umesto da lečimo pacijenta. Cilj je pronalaženje najmanje invazivnog metoda i najkraćeg mogućeg vremenskog perioda za postavljanje adekvatne dijagnoze tuberkuloznog pleuritisa i započinjanje lečenja [23]. Naše iskustvo pokazuje visok procenat uspešnog terapijskog odgovora na primenu antituberkulozne terapije nakon dijagnostikovanja tuberkuloznog pleuritisa na osnovu rezultata ADA.

## ZAKLJUČAK

ADA je visoko senzitivna i specifičan biomarker, dostupan je i jeftin, pa bi ga trebalo koristiti kad god je moguće. Reč je o brzom, efikasnom i ekonomičnom na-

scoring systems. One of the most commonly used ratios is the serum LDH/pleural ADA (cancer ratio), where values above 20 suggest malignant pleural effusion [20]. In high TB prevalence regions and in patients with the presence of lymphocyte-predominant exudate with clinical suspicion of TB and ADA >40 IU/L there is a positive predictive value of 98%. ADA is the most frequently used test for diagnosing tuberculosis in areas with moderate altitude prevalence of the disease, while in areas with low prevalence ADA can be used as an exclusion test [18,21]. The disadvantage of this biomarker is that it does not provide information on cultivation and the type of mycobacteriosis and drug resistance [21].

The role of ADA is also important in treatment response during the follow up period. In a prospective study from India, the authors showed that the level of serum ADA could be useful for monitoring the anti-tuberculosis effect. The results showed a significant difference between ADA levels before and after the tuberculosis treatment ( $p < 0.001$ ) [22].

Based on all the above-mentioned reasons, we use ADA in our daily practice in the pulmonology department. It is a fast and simple way to confirm TP when other diagnostic procedures have negative results. It is important that in the 21<sup>st</sup> century we do not waste precious time waiting for cultures and repetition of pleural thoracentesis and pleural biopsy instead of providing treatment. The goal is the least invasive method and the minimal time for establishing the adequate diagnosis of TP and starting the treatment [23]. Our experience shows a high rate of successful response to the application of anti-tuberculosis therapy after the diagnosis of TP based on ADA results.

## CONCLUSION

ADA is a sensitive and specific biochemical marker; it is available and cheap, and it should be used whenever possible. It is a fast, efficient, and economical way for clarifying the etiology of the pleural effusion as tuberculous pleurisy. Implementation of this biomarker in the routine practice shortens the path to the adequate TP diagnosis and the treatment of these patients. Further research and studies must go in the direction of diagnostics of such highly specific biomarkers for rapid detection of various diseases.

**Conflict of interest:** None declared.

činu za utvrđivanje etiologije pleuralnog izliva kao tuberkuloznog pleuritisa. Uvrščivanje ovog biomarkera u rutinsku praksu skraćuje put do adekvatne dijagnoze tuberkuloznog pleuritisa i lečenja ovih pacijenata. Dalja istraživanja i studije trebalo bi da se kreću u pravcu dijagnostike ovako visokospecifičnih biomarkera za brzo otkrivanje različitih bolesti.

**Sukob interesa:** Nije prijavljen.

## LITERATURA / REFERENCES

- Shaw JA, Koegelenberg CFN. Pleural Tuberculosis. *Clin Chest Med.* 2021;42(4):649-66. doi: 10.1016/j.ccm.2021.08.002.
- World Health Organization. Global Tuberculosis Report 2019. [Internet] Geneva: World Health Organization. 2019. Available from: <https://www.who.int/publications/i/item/9789241565714/>.
- Moule MG, Cirillo JD. Mycobacterium tuberculosis Dissemination Plays a Critical Role in Pathogenesis. *Front Cell Infect Microbiol.* 2020; 10:65. doi: 10.3389/fcimb.2020.00065.
- Shaw JA, Diacon AH, Koegelenberg CFN. Tuberculous pleural effusion. *Respirology.* 2019;24(10):962-71. doi: 10.1111/resp.13673.
- Jankovic J, Jandric A, Jordanova E. Vanbolnički stečene pneumonije (community acquired pneumonia - CAP). *Halo* 194. 2022;28(3):82-7. doi: 10.5937/halo28-40900.
- Porcel JM. Pleural fluid biomarkers: beyond the Light criteria. *Clin Chest Med.* 2013 Mar;34(1):27-37. doi: 10.1016/j.ccm.2012.11.002.
- Xi S, Sun J, Wang H, Qiao Q, He X. Diagnostic Value of Model-Based Iterative Algorithm in Tuberculous Pleural Effusion. *J Healthc Eng.* 2022; 2022:7845767. doi: 10.1155/2022/7845767.
- Popevic S, Ilic B. Brohoskopija u dijagnostici i lečenju endobronhijalne tuberkuloze. In: Stjepanović M, Popević S, Dimić-Janjić Sanja, editors. *Odabrana poglavlja iz pulmologije.* Beograd: Medicinski fakultet Univerziteta u Beogradu; 2023.
- Petborom P, Dechates B, Muangnoi P. Differentiating tuberculous pleuritis from other exudative lymphocytic pleural effusions. *Ann Palliat Med* 2020;9(5):2508-15. doi: 10.21037/apm-19-394.
- Jeon D. Tuberculous pleurisy: an update. *Tuberc Respir Dis (Seoul).* 2014;76(4):153-9. doi: 10.4046/trd.2014.76.4.
- Tousheed SZ, Ranganatha R, Kumar H, Sagar C, Manjunath PH, Philip D, et al. Yield of pleural biopsy in different types of tubercular effusions. *Indian J Tuberc.* 2020;67(4):523-7. doi: 10.1016/j.ijtb.
- Lo Cascio CM, Kaul V, Dhooria S, Agrawal A, Chaddha U. Diagnosis of tuberculous pleural effusions: A review. *Respir Med.* 2021; 188:106607. doi: 10.1016/j.rmed.2021.106607.
- Ali MS, Light RW, Maldonado F. Pleuroscopy or video-assisted thoracoscopic surgery for exudative pleural effusion: a comparative overview. *J Thorac Dis.* 2019;11(7):3207-16. doi: 10.21037/jtd.2019.03.86.
- Javadi J, Dobra K, Hjerpe A. Multiplex Soluble Biomarker Analysis from Pleural Effusion. *Biomolecules* 2020; 10(8):1113. doi: 10.3390/biom10081113.
- Aggarwal AN, Agarwal R, Sehgal IS, Dhooria S. Adenosine deaminase for diagnosis of tuberculous pleural effusion: A systematic review and meta-analysis. *PLoS One.* 2019;14(3): e0213728. doi: 10.1371/journal.pone.0213728.
- Jankovic J, Djurdjevic N, Jandric A, Mitic J, Bojic Z. Case Report of Rare Presentation Double Primary Tumor - Colon Carcinoma and Malignant Pleural Mesothelioma. *JOJ Case Stud.* 2022; 13(5): 555872. doi: 10.19080/JOJCS.2022.13.555872.
- Lee J, Park JE, Choi SH, Seo H, Lee SY, Lim JK, et al. Laboratory and radiological discrimination between tuberculous and malignant pleural effusions with high adenosine deaminase levels. *Korean J Intern Med.* 2022;37(1):137-45. doi: 10.3904/kjim.2020.246.
- Zeng T, Ling B, Hu X, Wang S, Qiao W, Gao L, et al. The Value of Adenosine Deaminase 2 in the Detection of Tuberculous Pleural Effusion: A Meta-Analysis and Systematic Review. *Can Respir J.* 2022; 2022:7078652. doi: 10.1155/2022/7078652.
- Shaw JA, Irusen EM, Diacon AH, Koegelenberg CF. Pleural tuberculosis: A concise clinical review. *Clin Respir J.* 2018;12(5):1779-86. doi: 10.1111/crj.12900.
- Lin L, Li S, Xiong Q, Wang H. A retrospective study on the combined biomarkers and ratios in serum and pleural fluid to distinguish the multiple types of pleural effusion. *BMC Pulm Med.* 2021;21(1):95. doi: 10.1186/s12890-021-01459-w.
- Jankovic J. Biomarkeri u dijagnostici pleuralnih izliva. U: Stjepanović M, Popević S, Dimić-Janjić Sanja, urednici. *Odabrana poglavlja iz pulmologije.* Beograd: Medicinski fakultet u Beogradu; 2023.
- Soedarsono S, Prinasetyo KWAI, Tanzilia M, Nugraha J. Changes of serum adenosine deaminase level in new cases of pulmonary tuberculosis before and after intensive phase treatment. *Lung India.* 2020;37(2):126-9. doi: 10.4103/lungindia.lungindia\_395\_19.
- Jovanović D, Antonijević G, Luković B, Ilić B. Multirezistentna tuberkuloza i ekstenzivna multirezistentna tuberkuloza – klinička slika i dijagnostika. In: Jovanović D, editor. *Klinički aspekti tuberkuloze.* Beograd: Medicinski fakultet Univerziteta u Beogradu; 2020. p. 165-77.